



# Synovial plica of the elbow and its clinical relevance

Przemysław Lubiowski<sup>1,2,3</sup>

Joanna Wałęcka<sup>1,2,3</sup>

Marcin Dziańach<sup>2</sup>

Jakub Stefaniak<sup>1,2,3</sup>

Leszek Romanowski<sup>3</sup>

- A synovial plica (fold) is normal anatomic finding, and occurs in 86–100% of cases; however, symptomatic plica is much less common (7.2–8.7% of all elbow arthroscopies).
- Synovial plica syndrome is a painful elbow condition related to symptomatic synovial plica.
- Synovial plica syndrome is diagnosed by clinical examination (lateral elbow pain) commonly accompanied by local tenderness, pain at terminal extension and/or painful snapping.
- Synovial plica syndrome may be mimicked by other elbow conditions, commonly tennis elbow, loose bodies, and degenerative arthritis.
- Magnetic resonance imaging or ultrasound scan may support diagnosis in correlation with clinical findings, but symptomatic plica may also be diagnosed as unexpected during elbow arthroscopy.
- The arthroscopic resection is effective and safe if conservative treatment fails.

**Keywords:** elbow; elbow arthroscopy; plica syndrome; snapping elbow; synovial plica; synovial fold

Cite this article: EFOR Open Rev 2020;5:549-557.

DOI: 10.1302/2058-5241.5.200027

Definition, clinical relevance, clinical picture, diagnosis and the treatment of the elbow synovial plica syndrome have brought some confusion. The literature in the scope of medical journals is rare. Even the terminology has not been uniformed and dealt with plicas, folds, fringes, menisci, or recesses.<sup>1–8</sup> Synovial plicae (or folds) of the elbow have been identified in the anterior or posterior compartments, but mostly around the radio-capitellar joint (RCJ).<sup>2,5,7–11</sup> Its presence both in adults and new-borns was described as early as 1931 by Boileau Grant and clinical relevance was reported by Moor in 1953.<sup>12,13</sup> Probably one of the most important issues for a synovial fold is that

its presentation and clinical significance may easily be either overestimated or underestimated. First of all, it is not clear when and which plica is the reason for a patient's symptoms. Second, symptoms related to the plicae are not characteristic and specific and rather mimic other common problems such as tennis elbow or degenerative arthritis. Therefore, the aim of this study was to evaluate all the available literature on elbow plica with the main focus of its clinical relevance. We wanted to find out hints for how to differentiate symptomatic from asymptomatic elbow folds, how to diagnose the syndrome, and finally what to expect from treatment.

## Methods

PUBMED and SCOPUS were searched with criteria of any words or phrases that could represent the human elbow plica and related problems, including 'plica' or 'fold' or 'fringe' or 'snapping' and 'elbow' or 'radio-humeral' or 'radio-capitellar'. The search was performed by two authors and resulted in 1244 items. All were revised on the basis of titles and abstracts. All non-human, non-English language and review papers were rejected. Two more studies were found based on initial paper analysis from references. Thirty studies fulfilled the criteria: 19 studies ( $n = 287$ ) reported the results of the treatment of the syndrome (Table 1), 11 studies addressed only diagnostic and morphological aspects. The types of studies were level III or IV and included a case-control,<sup>3</sup> a case-series,<sup>8</sup> a case report,<sup>12</sup> a prospective cohort study<sup>1</sup> and a cadaveric study.<sup>6</sup>

## Synovial fold

The elbow plica is a formation of prominent fold of synovial membrane. Numerous variations of location, shape, structure and size have been described. In general, the elbow plica is considered physiological.<sup>3,5,7,10,14</sup> Isogai et al hypothesized that folds found in adults originate from

**Table 1.** List of studies on elbow plica syndrome and its treatment.

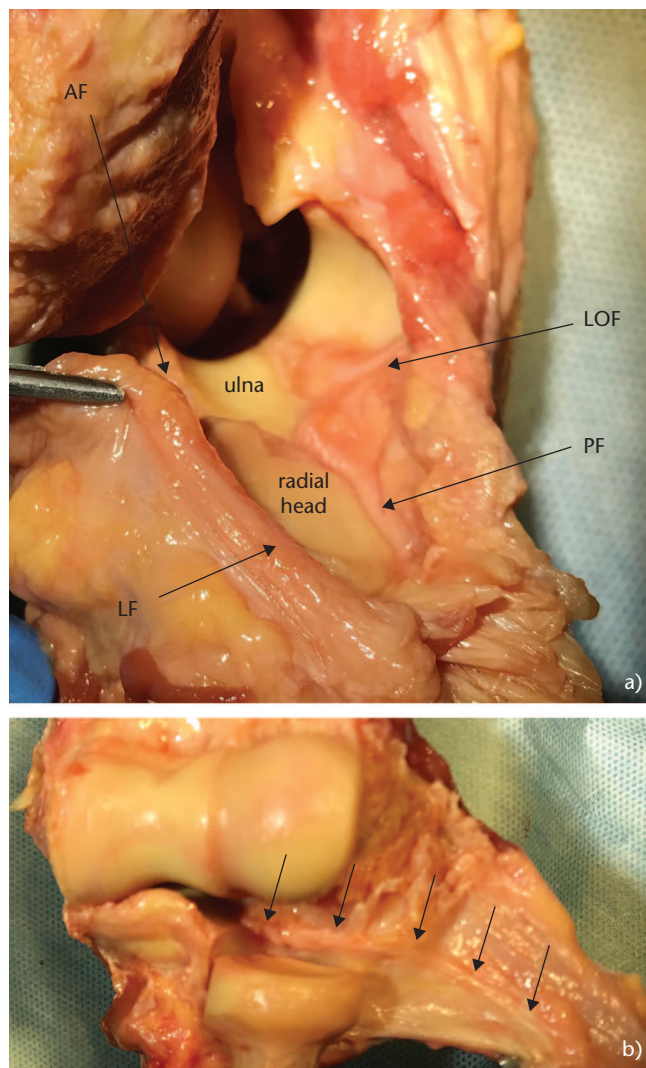
number	First author of the study	Year of publication	Number of cases	Type and level of publication	Sex		Age	Reported aetiology		Imaging for confirmation	Location	Technique of plica resection	Successful treatment		Clinical relevance	
					Female	Male		Sport	Traumatic				Labour /overuse	Number of cases		%
1	Akagi <sup>1</sup>	1998	1	Case report, level IV	1	27		1		Pneumo-arthrogram	Anterior RCJ	Open	1	100%	- Resolution of symptoms - Return to normal activity	- Radial head cartilage wear - Chondroid metaplasia of synovial plica
2	Clarke <sup>4</sup>	1988	3	Case report, level IV	3	18, 29, 48	2	1		Arthroscopic RCJ	Anterior RCJ	Arthroscopic	3	100%	- Resolution of symptoms (up to 13 m FU), - return to normal activity (including sports)	- Chondromalacia in RCJ ('kissing lesion' with plica) - No benefit with steroid injection - Repetitive injury to cause the syndrome and plica hypertrophy
3	Sakai <sup>17</sup>	1999	2	Case report, level IV	2	15, 17	2			CT	Posterior RCJ	Open	2	100%	- Resolution of symptoms - Return to normal activity (including sports)	- Chronic fibrous synovitis on histology - Overloading due to sport causing synovitis of congenitally large plica
4	Antuna <sup>18</sup>	2001	14	Case series, level IV	6	36 (27-48)		9		Arthroscopic (8), MR (6)	Anterior RCJ	Arthroscopic	12	86%	- 79% complete pain relief - 7% mild pain on overloading - 1 recurrence with 2 more subsequent arthroscopies for same patient - no direct complications, - Resolution of symptoms (up to 2 years FU),	- Flexion-pronation test described - 50% had plica diagnosed for the first time at arthroscopy - Need for complete resection for effective treatment - 93% cartilage erosions in RCJ - 75% of cases with primary diagnosis of loose body - Inflamed synovial fold on histology
5	Awaya <sup>2</sup>	2001	8	Cadaveric study and case series, level IV	8	28, 3 (17-37)	2			MR, surgical	Olecranon	Arthroscopic	8	100%	- Resolution of symptoms (up to 1 year FU)	- Symptomatic folds thickened - Meniscus type of structure on histology - Hypertrophy of synovial fold due to repetitive injury and impingement - Bilateral fold, no overuse in history
6	Huang <sup>6</sup>	2005	1	Case report	1	20				MR arthrography	Antero RCJ	Arthroscopic	1	100%	- Resolution of symptoms (up to 3 months FU),	- 58% of cases with chondromalacia RCJ - Throwing athletes and golfers
7	Fukase <sup>30</sup>	2005	1	Case report, level IV	1	12				MR	Anterior-to-posterior	Open	1	100%	- Resolution of symptoms (up to 1 year FU)	- Bilateral fold, no overuse in history
8	Kim <sup>11</sup>	2006	12	Case series, level IV	3	21, 6 (17-33)	12			MR, MR arthrography, arthroscopic	Posterior RCJ	Arthroscopic	9	92%	- 67% no symptoms, 25% slight discomfort, 8% occasional pain - 29% persistent mechanical symptoms non-painful; satisfied, - 92% return to sport	- Primarily misdiagnosed with tennis elbow - Bilateral plica syndrome due to overuse
9	Ruch <sup>22</sup>	2006	10	Case series, level IV	6	40 (18-60)				Arthroscopic	Posterior RCJ	Arthroscopic	10	100%	- Successful treatment; full recovery (no pain, no limitation, no symptoms); 4 had additional procedures (ligament repair, ulnar nerve transposition, tennis elbow); no instability	- Snapping meniscus
10	Tateishi <sup>20</sup>	2006	1	Case report, level IV	1	64	1			MR arthrography	Anterior RCJ	Open	1	100%	- Significant improvement (up to 2 years FU)	- Paediatric patients with painful contracture
11	Kang <sup>21</sup>	2010	2	Case report, level IV	2	28, 38				MR arthrography	Anterior-to-posterior	Arthroscopic	2	100%	- Resolution of symptoms (up to 2 years FU)	
12	Meyers <sup>35</sup>	2012	1	Case report, level IV	1	13				MR, arthroscopic	Posterior RCJ	Open	1	100%	- Significant improvement	

(Continued)

Table 1. (Continued)

number the author of the study	First author of the study	Year of publication	Number of cases	Type and level of publication	Sex		Age	Reported aetiology		Imaging for confirmation	Location	Technique of plica resection	Successful treatment		Clinical relevance	
					Female	Male		Sport	Traumatic				Labour /overuse	Number of cases		% of cases
13	Steinert <sup>19</sup>	2010	3	Case report, level IV	3	0	26, 53, 65	1	1	MR	Posterior RCJ	Arthroscopic	2	67%	- All patients relieved from snapping - 1 patient with persistent pain after surgery due to chondromalacia	- 1/3 RCJ cartilage lesions grade II/III - No complications - Arthroscopic intervention should not be delayed in snapping elbow, as subsequent erosion of articular cartilage can be prevented by early resection of synovial plica - Large study: 121 out of 600 patients with lateral elbow pain
14	Rajeev <sup>24</sup>	2015	121	Case series, level IV	29	92	38 (24–56)			MR, arthroscopic	Humero- radial	Arthroscopic	114	93%	- Results by Modified Elbow Score: 76% excellent, 18% good, 3 fair, 3 poor - Superficial infection in 2 cases	- 13 (20%) grade I cartilage lesions in RCJ
15	Brahe Pedersen <sup>15</sup>	2017	60	Case series, level IV	17	43	44 (42–46)	32		US	Posterior RCJ	Arthroscopic	27	47%	- 47% satisfactory based on Oxford Elbow Score - 18% of patients with normal score - No complications	- Dynamic US to visualize the cause of snapping in the elbow
16	Bjerre <sup>25</sup>	2018	2	Case report, level IV	2	0	16, 16			US	Anterior RCJ	Arthroscopic	1	50%	- Resolution of snapping and satisfied at 3 year FU - 1 patient slight tenderness from time to time	- Dynamic US to visualize the cause of snapping in the elbow
17	Feller <sup>26</sup>	2018	1	Case report, level IV	1	0	59			MR/US	Anterior-to- posterior	Open	1	100%	- Resolution of symptoms and no impairment at 2 year FU - 85% grip strength of contralateral side	- Dynamic US to visualize the cause of snapping in the elbow - Re-operation
18	Lee <sup>8</sup>	2018	20	Case series, level IV	9	11	42 (18–63)	5		MR, arthroscopic	Posterior 15, anterior RCJ 5	Arthroscopic	18	90%	- All improved: pain from 6.3 to 1.0, DASH 26.4 to 14.1, MEPI from 66 to 89 - Based on MEPI: 60% excellent, 30% good, 10% fair outcome - No direct complications - Later: 1 patient loose body and early arthritis; need for additional arthroscopy 5 years after initial surgery - 35% very satisfied, 45% mostly satisfied, 20% neutral	- On MRI thickness and length of plica significantly larger than normal value (on average 4x9 mm) - Elbow arthroscopy important tool for diagnosis and treatment of plica syndrome
19	Park <sup>24</sup>	2019	24	Case series, level III	18	6	44+/- 10.4	3		MR, arthroscopic	Posterior RCJ	Arthroscopic	20	86%	- Significant improvement: DASH from 37 to 9; MEPI from 57 to 96 - 71% excellent, 29% good, - Intermittent snapping 4%, persistent limitation of extension in 8%	- Description and value of clinical tests for plica syndrome - Primarily no patient referred as plica (20 tennis elbow, 1 OSD, 1 loose body, 1 synovitis, 1 synovitis and loose body) - On MR: plica in 70%, - 29% had chondromalacia at RCJ

Note: RCJ, radio-capitellar joint; MR, magnetic resonance imaging; US, ultrasound scan; OSD, osteochondritis dissecans; FU, follow-up; DASH, Disabilities of the Arm, Shoulder and Hand score; MEPI, Mayo Elbow Performance Index.

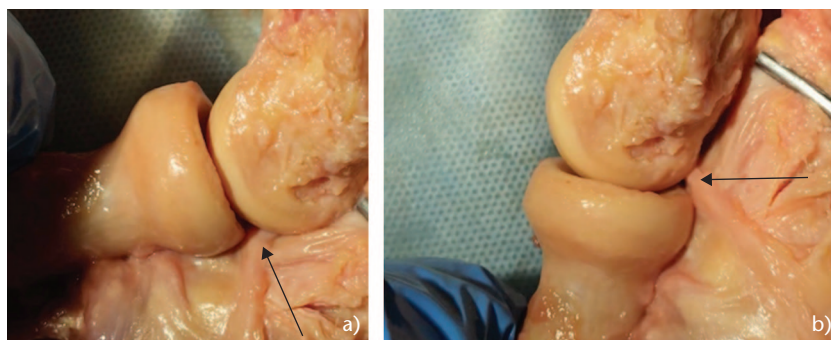


**Fig. 1** Anatomic pictures of synovial fold localization around the radio-humeral joint. (a) Arrows point to particular fold locations; (b) a dissected capsule around the radio-capitellar joint, arrows point to the radio-capitellar fold closely associated with the annular ligament.  
 Note. AF, anterior fold; LF, lateral fold; PF, posterior fold; LOF, lateral olecranon fold.

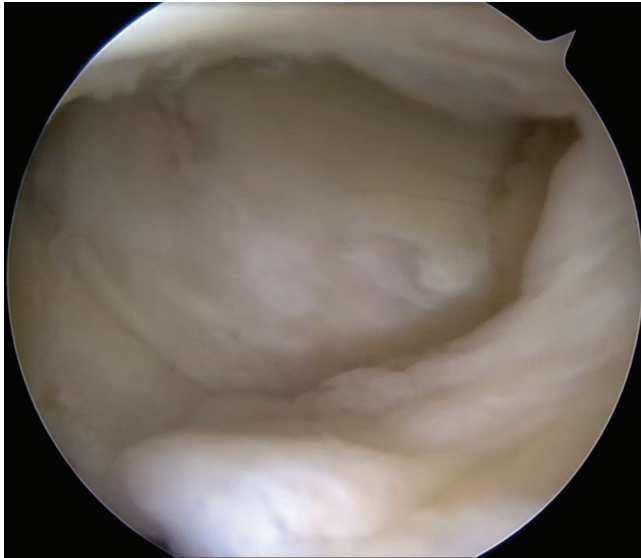
the corresponding structures in embryos and undergo significant modifications from homogenous structures intermingled with the annular ligament to more heterogenous appearance in adults.<sup>10</sup> A plica may be a simple space filler, occupying non-articular indentations (Fig. 1).<sup>12,13</sup> However, it may serve as load disperser and provide cushioning during the process of flexion and extension (Fig. 2).<sup>5,10</sup> Over the lifetime, forces at the elbow tend to transform the synovium into a soft and villous degenerative fold. In some instances, impinging produces larger, thicker and harder structures, leading to mechanical symptoms (pain, snapping, contracture). Overgrowing folds coexisting with the cartilage lesions on the radial head have been found in some reports (Fig. 3, Fig. 4).<sup>8,15</sup> The defining of location has been the subject of some confusion and is mostly based on a description of the fold based on either cadaveric or imaging studies with no relation to possible symptoms.<sup>2,3,8</sup> Isogai et al<sup>10</sup> and Cerezal et al achieved more comprehensive description, distinguishing the following (Fig. 1a):<sup>9</sup>

- anterior – thin part of the radio-humeral synovial fold, occurring in 67–100% of cases;<sup>10,16</sup>
- lateral – a thin, small, crescent or a meniscoid shape, in 5–20%;<sup>10,16</sup>
- posterior – between the greater and lesser sigmoid cavities and radio-humeral surfaces, merges with lateral fold anteriorly and lateral olecranon fold, in 86–100%;<sup>5,10,16</sup>
- lateral olecranon – on the lateral margin of olecranon under anconaeus muscle, in 28–33%;<sup>2,5,7</sup>
- circumferential – the continuous plate, combining anterior and posterior, in 2–12%.<sup>5,10</sup>

The histological analysis found mostly fibro-adipose tissue with moderate vascularization and abundant nerve endings in the periphery, thus indicating that it may be a significant source of pain.<sup>5,9,10</sup> Symptomatic plica presented with signs of synovitis and fibrotic transformation.<sup>2,17</sup>



**Fig. 2** Anatomic pictures of a posterior fold cushioning a radio-capitellar joint at flexion (a) and extension (b).



**Fig. 3** Arthroscopic picture from the posterolateral view showing a plica impinging against the radial head with the degenerative cartilage defects.

### Clinical relevance

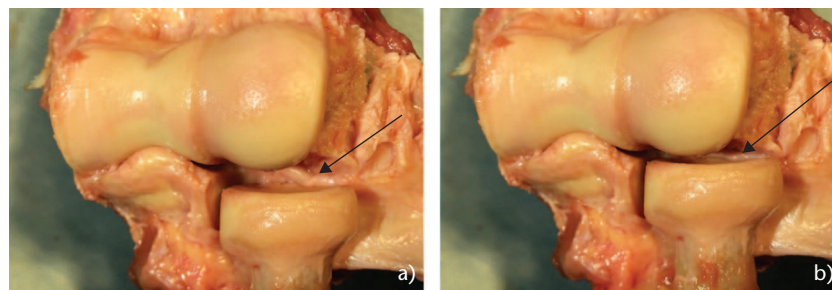
Symptomatic elbow plica may present with the variety of symptoms referred to as synovial plica syndrome. Major clinical challenges are how to diagnose plica syndrome, since its symptoms are not specific, and how to distinguish a normal fold from a symptomatic one. The exact occurrence of a synovial fold and related clinical problems are not clear. Plica seems to be a normal finding. Husarik et al and Choi et al, on the basis of a magnetic resonance imaging (MRI) of asymptomatic volunteers, identified a posterior (radio-capitellar) fold in 92–98% of cases.<sup>3,7</sup> Two large cadaveric studies by Duparc et al ( $n = 50$ ) and Isogai et al (examining 179 adult and 40 embryonic cases) found the presence of a synovial fold in 86% and 100% of cases respectively.<sup>5,10</sup> Occurrence of pathological plica and how often one could expect to see a patient with a plica-related problem is another issue. An approximate idea is given by some clinical studies. Antuna and O'Driscoll reported in

their clinical studies an arthroscopic treatment of synovial fold syndrome.<sup>18</sup> The procedure was performed in 8.7% of all elbow arthroscopies in their institution at the study period. Out of all elbow arthroscopies reported by Kim et al, 11% had plica to be addressed that correlated with the symptoms and another 15% that had an asymptomatic synovial fold.<sup>11</sup>

### Clinical picture

The aetiological factors were mostly not identified; however, folds could result from repetitive injury or overload (reported in five studies, 19 out of 26 patients) or manual work (three studies, 33 out of 64 patients) and trauma (four studies, 24 out of 61 patients).<sup>2,4,11,17–20</sup> They could also accompany degenerative or inflammatory diseases.<sup>2,10,11</sup> In two studies (three cases) folds appeared histologically as meniscus and could be considered as congenital.<sup>6,21</sup>

Typically, patients would complain of clicking or snapping during elbow motion, which may result in catching or locking by the interposed tissue. They would often report pain on the lateral side of the elbow, aggravated at the extremes of motion. In some patients locking fold could be associated with slight limitation of motion. Examining the elbow would show local tenderness at the posterolateral aspect of the RCJ and in some cases in the antero-lateral side. Antuna and O'Driscoll used the flexion-pronation manoeuvre in the clinical evaluation of the plica syndrome.<sup>18</sup> When performed, the elbow is flexed in pronation that can cause snapping and/or pain at the posterolateral aspect of the elbow. Ruch et al found clicking or pain at the terminal extension and in the supinated elbow in all their patients.<sup>22</sup> Commandre et al reported a slight limitation of extension.<sup>23</sup> Table 2 presents the occurrence of a specific clinical finding in patients with the elbow plica syndrome as reported in three studies.<sup>8,11,24</sup> Most common were tenderness over the posterolateral aspect of the RCJ and pain at the terminal extension. A painful snapping was present in 45% of cases. The flexion-pronation manoeuvre was present in only 34% of cases.

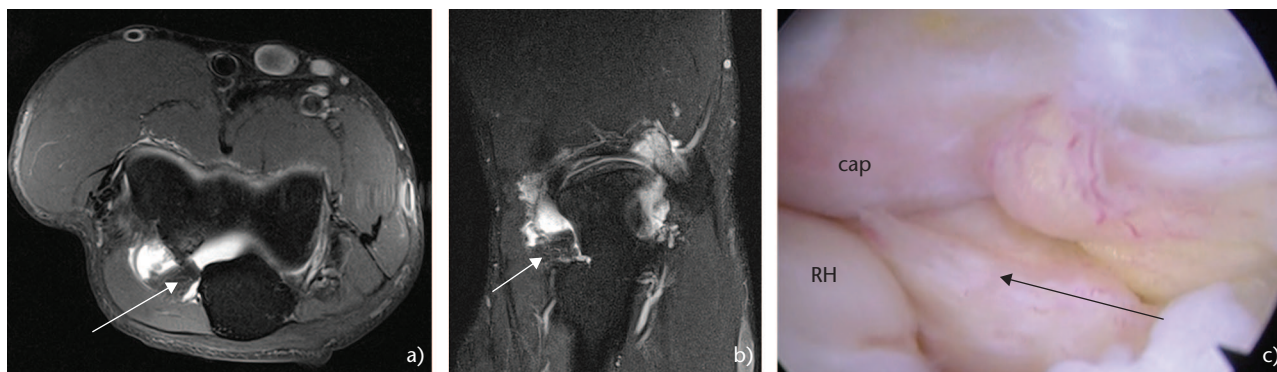


**Fig. 4** Anatomic pictures representing a possible positioning effect of the axial loading ((a) distraction, (b) compression) on radio-capitellar capsule and synovial plica (arrows).

**Table 2.** The occurrence of specific findings during a clinical examination.

Clinical tests	Lee et al <sup>8</sup>		Kim et al <sup>11</sup>		Park et al <sup>24</sup>		Summary of pooled data	
	n = 20	%	n = 12	%	n = 24	%	n = 56	%
Tenderness of RCJ	13	65	10	83	20	83	43	77
Pain at terminal extension	13	65	8	67	20	83	41	73
Painful snapping	9	45	7	58	9	38	25	45
+ Flexion-pronation test	8	40	3	25			11	34
Extension deficit	6	40	2	17	6	25	14	25
Catching	10	50						
Swelling			3	25				
+ Resisted extension at anconaeus			6	50				

Note. RCJ, radio-capitellar joint; n = number of patients in the study.



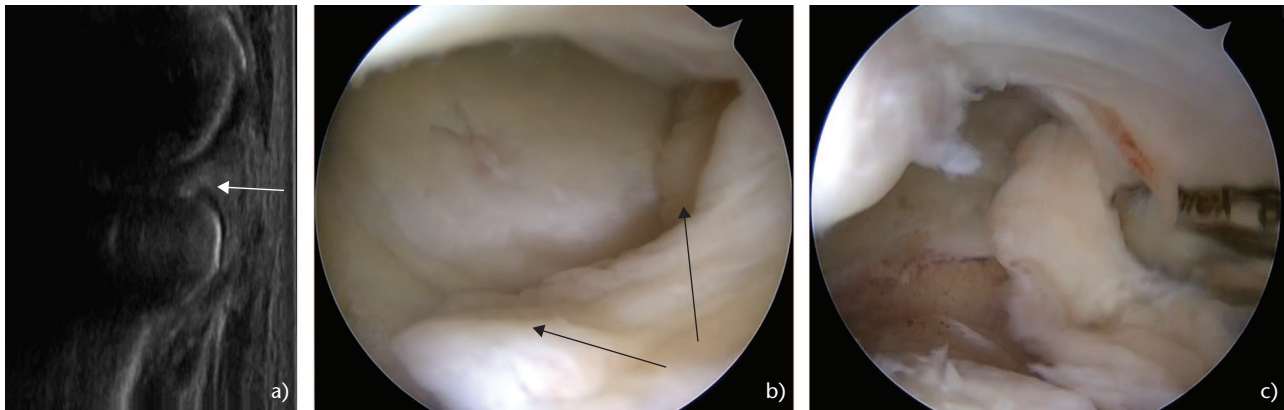
**Fig. 5** The posterior plica of a radio-capitellar joint. Magnetic resonance imaging (a, b), white arrows pointing to the plica; arthroscopic picture from posterolateral of the posterior plica, (c) black arrow pointing to the plica.

Note. RH, radial head; cap, capitellum.

A differential diagnosis is crucial since many symptoms are not specific and may be mimicked by other conditions such as a tennis elbow, loose bodies, early degenerative changes, osteochondritis dissecans or posterolateral rotatory instability.<sup>25–27</sup> Fifty per cent of patients in Kim et al’s study and 100% of patients in Antuna and O’Driscoll’s and in Park et al’s studies were referred to their institutions primarily for other reasons.<sup>11,18,24</sup> Snapping may occur in such situations as loose bodies, osteoarthritis or osteochondritis dissecans as well as in case of a torn or loose annular ligament, instability, triceps anomaly or overgrowth.<sup>28,29</sup> Pain or local tenderness most commonly could be confused with tennis elbow or synovitis. A limited extension could derive from degenerative changes, a locked loose body or rheumatoid arthritis. A negative test with anaesthetic injection at the lateral epicondyle may also exclude tendinopathy and raise the suspicion of a plica as the source of pain. A lidocaine test can also be performed by injection into the fold, preferably under ultrasonographic (US) guidance in order to observe any relief of pain. A lidocaine test could be combined with steroid injection for therapeutic purposes.

## Imaging

Imaging studies are very helpful to identify a synovial fold around the radio-capitellar or ulno-humeral joints.<sup>7,30–32</sup> X-rays will typically be normal in the presence of synovial plica syndrome. In four out of 18 studies (in 62 cases) the diagnosis was confirmed only by arthroscopy. For the majority of cases, MRI was used (in 12 studies, 179 cases) or ultrasound scan (in two studies, 60 cases). MRI seems to allow for a comprehensive evaluation of particular planes and measurements (Fig. 5). Imaging should also be used to differentiate between a normal plica and a pathological, clinically relevant one. Symptomatic folds tend to be thick and fibrotic with signs of chronic synovitis.<sup>1</sup> Choi et al compared MRI of symptomatic and asymptomatic elbow folds.<sup>3</sup> The former showed to be almost twice as large: mediolateral dimensions of 9 mm as opposed to 5 mm and in the lateral of 9 mm vs. 7.5 mm respectively. Symptomatic folds would cover over 30% of the radial head while asymptomatic would only cover 18%. In our experience, as well as being confirmed in other studies, a high-resolution ultrasound scan performed by a musculoskeletal radiologist proved to be a



**Fig. 6** A posterior and lateral plica of the radio-capitellar joint. The ultrasound scan (a), white arrows pointing to the plica; arthroscopic picture from posterolateral of the posterior plica and lateral plica (b), black arrows pointing to plicae; an arthroscopic resection of the plica (c).

quick and practical tool, and was not only able to identify the plica, but also correlate its presence with tenderness or showing the evident impingement on dynamic testing (Fig. 6a).<sup>16,33</sup> The ultrasound scan may also exclude other pathologies such as tendinopathy, loose bodies, impinging osteophytes and snapping triceps. Finally, the elbow arthroscopy allows for a direct visualization anteriorly and posteriorly as well as the dynamic evaluation of the plica for final confirmations (Fig. 5c, 6b, 6c).

## Treatment

There is a general consensus that elbow plica syndrome should be initially treated with conservative therapy. However, there is no data on what type of conservative therapy should be applied, or on their effectiveness. Initially, we tend to advise patients to decrease the amount of physical activity, restore a range of motion with a guided physiotherapy and use non-steroidal anti-inflammatory drugs.<sup>11,15,34</sup> In some cases, a steroid injection may be considered, and possibly used as part of an anaesthetic test for confirmation, preferably under ultrasound scan guidance.<sup>8,34</sup> Operative treatment is advocated when the initial attempt at conservative therapy fails. Ruch et al reported the results of arthroscopic treatment for patients who were symptomatic for at least six months despite non-operative therapy.<sup>22</sup> However, they have admitted that for most of the patients the initial diagnosis was tennis elbow. Others waited a shorter amount of time with the decision for surgical debridement – at least three months of symptoms refractory to conservative treatment.<sup>8,11,15</sup> In previous studies both open and arthroscopic procedures were used to resect the pathologic plica. We have looked at the results reported in literature (Table 1). Nineteen studies, of different scientific quality, published results of a treatment of 288 patients. Male-to-female ratio

was 2.2 and the age of patients ranged from paediatric cases to the elderly population (12 to 64 years) with an average pooled mean of 38.7 years.<sup>19,35</sup> In 126 patients, a fold was resected from the posterolateral region of the radio-capitellar joint and in 20 cases from the anterolateral. In one large study a fold was described as a humero-radial without a more precise description in 121 cases.<sup>34</sup> A vast majority of patients were treated using arthroscopic resection ( $n = 280$ ) and only in eight cases using open resection. The treatment was successful in 233 patients (81%), although the criteria of effectiveness were equivocal. We have considered treatment as successful if the authors reported resolution of symptoms or outcome assessment showing excellent or good results (Table 1). In seven studies, coexisting radio-capitellar chondromalacia was reported in 33 cases out of 104 patients (33%) or even 'kissing lesion' of plica against cartilage defect. Therefore, in case of symptomatic impinging plica (e.g. confirmed in dynamic US) and no resolution after conservative measures, arthroscopic removal should be considered without a significant delay to avoid possible secondary cartilage degenerative changes. Only few complications were reported: two superficial infections (0.7%), four patients in the pooled group were re-operated, one case was diagnosed with degenerative arthritis.

To summarize, a typical workup for the patient with suspected elbow plica syndrome starts with clinical evaluation. We should consider elbow plica syndrome with lateral elbow pain that is accompanied by some form of mechanical symptoms (snapping, slight painful contracture). Long-term pain treated as tennis elbow that had not improvement over conservative treatment should invite our suspicion. A painful radio-capitellar joint (mostly posteriorly) with painful extension as well as reproduction of snapping would add to the picture of the syndrome. X-ray is the first choice of imaging modality.

mostly to exclude other possible reasons for pain (osteoarthritis, loose osseous bodies). We typically use ultrasound scan to diagnose the plica and exclude other conditions. Pathological folds are usually larger (> 7 mm), solid and fibrotic, and impinge at the limits of motion. Initial treatment in most cases is conservative. If the treatment lasting at least three months fails, arthroscopic treatment is proposed to the patient. We do not wait usually too long with surgery if the patient has had refractory symptoms for a long time, been treated for other conditions and in the case of thick fibrotic synovial plica causing clear painful impingement-related contracture. Usually recovery is quick and most patients may expect to return to normal activity within 1–3 months.

## Conclusions

A synovial plica of the elbow is generally a normal finding mostly located around the radio-capitellar joint. However, when symptomatic, it seems to change appearance to a larger, inflamed and fibrotic structure. Elbow plica syndrome is mostly manifested with lateral-sided elbow pain, commonly accompanied by local tenderness and a painful limitation of movement, sometimes with mechanical symptoms. Symptoms may mimic other conditions resulting in misdiagnosis. It is not infrequent that plica syndrome is wrongly diagnosed from a primarily different identification. Clinical suspicion may efficiently be supported by use of MRI or ultrasound scan. If symptoms persist despite initially non-operative management, surgical treatment with arthroscopic resection has been shown to be effective and safe.

### AUTHOR INFORMATION

<sup>1</sup>Sport Trauma and Biomechanics Unit, University of Medical Sciences, Poznań, Poland.

<sup>2</sup>Rehasport Clinic, Poznań, Poland.

<sup>3</sup>Department of Traumatology, Orthopaedics and Hand Surgery, University of Medical Sciences, Poznań, Poland.

Correspondence should be sent to: Przemysław Lubiowski, Rehasport Clinic, Ul. Górecka 30, 60-201 Poznań, Poland.

Email: p.lubiowski@rehasport.pl

### ICMJE CONFLICT OF INTEREST STATEMENT

PL reports Board membership of Rehasport Clinic, employment by the University of Medical Sciences, Poznań, a grant from the National Center for Research and Development, payment for lectures including service on speakers' bureaus from Arthrex and Smith & Nephew, holds stock in non-medical organizations, publicly available from the stock market and is an Assistant Editor of *EFORT Open Reviews*, all outside the submitted work.

The other authors declare no conflict of interest relevant to this work.

### FUNDING STATEMENT

No benefits in any form have been received or will be received from a commercial party related directly or indirectly to the subject of this article.

### LICENCE

© 2020 The author(s)

This article is distributed under the terms of the Creative Commons Attribution-Non Commercial 4.0 International (CC BY-NC 4.0) licence (<https://creativecommons.org/licenses/by-nc/4.0/>) which permits non-commercial use, reproduction and distribution of the work without further permission provided the original work is attributed.

### REFERENCES

- Akagi M, Nakamura T.** Snapping elbow caused by the synovial fold in the radiohumeral joint. *J Shoulder Elbow Surg* 1998;7:427–429.
- Awaya H, Schweitzer ME, Feng SA, et al.** Elbow synovial fold syndrome: MR imaging findings. *AJR Am J Roentgenol* 2001;177:1377–1381.
- Choi SH, Ji SK, Lee SA, Park MJ, Chang MJ4.** Magnetic resonance imaging of posterolateral plica of the elbow joint: asymptomatic vs. symptomatic subjects. *PLoS One* 2017;12:e0174320.
- Clarke RP.** Symptomatic, lateral synovial fringe (plica) of the elbow joint. *Arthroscopy* 1988;4:112–116.
- Duparc F, Putz R, Michot C, Muller JM, Fréger P.** The synovial fold of the humeroradial joint: anatomical and histological features, and clinical relevance in lateral epicondylalgia of the elbow. *Surg Radiol Anat* 2002;24:302–307.
- Huang GS, Lee CH, Lee HS, Chen CY.** A meniscus causing painful snapping of the elbow joint: MR imaging with arthroscopic and histologic correlation. *Eur Radiol* 2005;15:2411–2414.
- Husarik DB, Saupe N, Pfirmann CW, Jost B, Hodler J, Zanetti M.** Ligaments and plicae of the elbow: normal MR imaging variability in 60 asymptomatic subjects. *Radiology* 2010;257:185–194.
- Lee HI, Koh KH, Kim JP, Jaegal M, Kim Y, Park MJ.** Prominent synovial plicae in radiocapitellar joints as a potential cause of lateral elbow pain: clinico-radiologic correlation. *J Shoulder Elbow Surg* 2018;27:1349–1356.
- Cerezal L, Rodriguez-Sammartino M, Canga A, et al.** Elbow synovial fold syndrome. *AJR Am J Roentgenol* 2013;201:W88–96.
- Isogai S, Murakami G, Wada T, Ishii S.** Which morphologies of synovial folds result from degeneration and/or aging of the radiohumeral joint: an anatomic study with cadavers and embryos. *J Shoulder Elbow Surg* 2001;10:169–181.
- Kim DH, Gambardella RA, Elattrache NS, Yocum LA, Jobe FW.** Arthroscopic treatment of posterolateral elbow impingement from lateral synovial plicae in throwing athletes and golfers. *Am J Sports Med* 2006;34:438–444.
- Boileau Grant JC.** Interarticular synovial folds. *Br J Surg* 1931;18:636–640.
- Moore M Jr.** Radiohumeral synovitis, a cause of persistent elbow pain. *Surg Clin North Am* 1953;33:363–371.
- Tsuji H, Wada T, Oda T, et al.** Arthroscopic, macroscopic, and microscopic anatomy of the synovial fold of the elbow joint in correlation with the common extensor origin. *Arthroscopy* 2008;24:34–38.
- Brahe Pedersen J, Kristensen PK, Mønsted P, Thillemann TM.** Short-term results after arthroscopic resection of synovial plicae in the radiohumeral joint: a case series of 64 procedures. *SICOT J* 2017;3:42.

16. Koh S, Morris RP, Andersen CL, Jones EA, Viegas SF. Ultrasonographic examination of the synovial fold of the radiohumeral joint. *J Shoulder Elbow Surg* 2007;16:609–615.
17. Sakai K, Kanamori M, Kitano S. Extension restriction of the elbow caused by a synovial fold: a report on 2 athletes. *Acta Orthop Scand* 1999;70:85–86.
18. Antuna SA, O'Driscoll SW. Snapping plicae associated with radiocapitellar chondromalacia. *Arthroscopy* 2001;17:491–495.
19. Steinert AF, Goebel S, Rucker A, Barthel T. Snapping elbow caused by hypertrophic synovial plica in the radiohumeral joint: a report of three cases and review of literature. *Arch Orthop Trauma Surg* 2010;130:347–351.
20. Tateishi K, Tsumura N, Matsumoto T, et al. Bilateral painful snapping elbows triggered by daily dumbbell exercises: a case report. *Knee Surg Sports Traumatol Arthrosc* 2006;14:487–490.
21. Kang ST, Kim TH. Lateral sided snapping elbow caused by a meniscus: two case reports and literature review. *Knee Surg Sports Traumatol Arthrosc* 2010;18:840–844.
22. Ruch DS, Papadonikolakis A, Campolattaro RM. The posterolateral plica: a cause of refractory lateral elbow pain. *J Shoulder Elbow Surg* 2006;15:367–370.
23. Commandre FA, Taillan B, Benezis C, Follacci FM, Hammou JC. Plica synovialis (synovial fold) of the elbow: report on one case. *J Sports Med Phys Fitness* 1988;28:209–210.
24. Park KB, Kim SJ, Chun YM, Yoon TH, Choi YS, Jung M. Clinical and diagnostic outcomes in arthroscopic treatment for posterolateral plicae impingement within the radiocapitellar joint. *Medicine (Baltimore)* 2019;98:e15497.
25. Bjerre JJ, Johannsen FE, Rathcke M, Krogsgaard MR. Snapping elbow: a guide to diagnosis and treatment. *World J Orthop* 2018;9:65–71.
26. Feller RJ, Gil JA, DaSilva M. Snapping at the lateral aspect of the elbow: a case report and review of the literature. *JBJS Case Connect* 2018;8:e48.
27. Ahmad CS, Vitale MA, ElAttrache NS. Elbow arthroscopy: capitellar osteochondritis dissecans and radiocapitellar plica. *Instr Course Lect* 2011;60:181–190.
28. Aoki M, Okamura K, Yamashita T. Snapping annular ligament of the elbow joint in the throwing arms of young brothers. *Arthroscopy* 2003;19:E4–E7.
29. Wightman JAK. Clicking elbow from a torn annular ligament. *J Bone Joint Surg* 1963;45B:380–381.
30. Fukase N, Kokubu T, Fujioka H, Iwama Y, Fujii M, Kurosaka M. Usefulness of MRI for diagnosis of painful snapping elbow. *Skeletal Radiol* 2005;35:797–800.
31. Mete BD, Gursoy M, Resnick D. A rare cause of posterolateral elbow pain: radiohumeral plica syndrome with typical MRI findings. *JBR-BTR* 2014;97:371.
32. Ruiz de Luzuriaga BC, Helms CA, Kosinski AS, Vinson EN. Elbow MR imaging findings in patients with synovial fringe syndrome. *Skeletal Radiol* 2013;42:675–680.
33. Celikyay F, Inanir A, Bilgic E, Ozmen Z. Ultrasonographic evaluation of the posterolateral radiohumeral plica in asymptomatic subjects and in patients with osteoarthritis. *Med Ultrason* 2015;17:155–159.
34. Rajeev A, Pooley J. Arthroscopic resection of humeroradial synovial plica for persistent lateral elbow pain. *J Orthop Surg (Hong Kong)* 2015;23:11–14.
35. Meyers AB, Kim HK, Emery KH. Elbow plica syndrome: presenting with elbow locking in a pediatric patient. *Pediatr Radiol* 2012;42:1263–1266.